



ASJO

ISSN 3006-2543 (Online)

ISSN 1990-3863 (Print)

AL-SHIFA JOURNAL OF OPHTHALMOLOGY

An Open Access, Peer Reviewed, Quarterly Journal of
AL-SHIFA TRUST EYE HOSPITAL

Vol. 20, No. 1, January – March 2024

Indexed in

WHO Index Medicus (IMEMR)

Asian Digital Library (ADL)

Pak Medinet

Pakistan Medical and Dental Council IP/033

ISSN 3006-2543 (Online)
ISSN 1990-3863 (Print)

**A
S
J
O**

Al-Shifa Journal of Ophthalmology

Vol. 20, No. 1, January – March 2024

QUARTERLY PUBLISHED

- **Editorial: An Elite Surgeon - Dethroning the Master Surgeon**
- **Conjunctival Bacterial Flora in Medical Students**
- **Eye and Hair Color Association for Forensic Identification**
- **Senile Cataract Induced Changes in Crystalline Lens**
- **Prevalence of Trachoma in Gilgit**
- **Topical Anesthesia for Extra Capsular Cataract Extraction**
- **Persistent High IOP after Vitrectomy (Case Report)**

Abstracts available at <https://www.asjoalshifaeye.org> and <http://www.pakmedinet.com/ASJO>
Manuscript submission through online platform ejmanager.com

Indexed in Index Medicus -EMR

Recognized by Pakistan Medical & Dental Council – IP/033

Al-Shifa Journal of Ophthalmology

Editorial inquiries should be addressed to Prof. Dr. Tayyab Afghani, Department of Orbit and Oculoplastics, Al-Shifa Trust Eye Hospital, Jhelum Road Rawalpindi, Pakistan.
Tel: 0092 51 5487821-25, Fax: 0092 51 5487827; Email: aqrcpio@yahoo.com ;
Website: www.asjoalshifaeye.org

- Editorial: An Elite Surgeon - Dethroning the Master Surgeon** 7
Rashid Zia
- Bacterial Flora of Conjunctiva in Medical Students of Mohtarma Benazir Bhutto Shaheed Medical College Mirpur Azad Kashmir** 9
Muhammad Usman Sadiq, Sara Najeeb, Umair Tariq Mirza, Fatima Akbar Shah, Muhammad Irfan Sadiq, Nazish Babar
- Beyond the Colors: Exploring the Association between Eye Color and Hair Color for Forensic Identification** 15
Zulfiqar Ali Buzdar
- Analysis Of Senile Cataract Induced Anatomical/Histo-Pathological And Biochemical Changes In Human Crystalline Lens** 21
Raja Faisal Zulfiqar, Raheela Adil, Syed Liaquat Ali, Adeel Zafar, Yousuf Khoso, Zen ul Abideen
- Prevalence of Trachoma in Gilgit, Pakistan: A Cross-Sectional Study at Tertiary Care Center** 27
Qaim Ali Khan , Muhammad Tahir, Yasir Iqbal , Nauroz Fatima, Qurat ul Ain Ghazanfar, Benish Ali
- A Novel Approach – Extra-capsular Cataract Extraction under Topical Anesthesia** 33
Muhammad Sharjeel, Hafiza Sadia Imtiaz, Muhammad Awais Ashraf, Muhammad Rizwan Khan, Irfan Ullah
- Persistent High Intraocular Pressure (IOP) After Phaco Vitrectomy In a Case of Ocular Trauma** 40
Xianxin Gao, Rong Zhao, Guohua Wang, Xiaonian Liu

Analysis Of Senile Cataract Induced Anatomical/Histo-Pathological And Biochemical Changes In Human Crystalline Lens

Raja Faisal Zulfiqar¹, Raheela Adil¹, Syed Liaquat Ali², Adeel Zafar², Yousuf Khoso³, Zen ul Abideen⁴

Abstract:

Objectives: To evaluate histopathological & physiological alterations in lenses affected by senile cataracts for a better understanding of the disease.

Methodology: After approval from the relevant ethical committee, analysis of 20 lenses removed surgically for Implant of a synthetic lens in patients aged 55 to 70 years was performed by histopathologic techniques using hematoxylin & eosin-stained slides and anatomical micrometric measurements. The duration of the study was approximately six (6) months. Random probability sampling was used.

Results: 55% of the crystalline lenses were found to have pathologic calcification, 45% of them showed enlarged or bladder cells, 40% presented with nuclear fibrosis, 20% had ectopic shifting of surface lining epithelial cells underneath the posterior capsule, and finger-like microstructures were seen projecting in the posterior wall of the capsule of the lenses in 15% of lenses.

Conclusion: Most of the lenses attributed more than one histopathological finding. A marked decrease in the size of epithelial cells was observed, whereas alterations in the thickness of the lenses were insignificant with a p-value of >0.05 . *Al-Shifa Journal of Ophthalmology 2024; 20(1): 21-26. © Al-Shifa Trust Eye Hospital, Rawalpindi, Pakistan.*

1. RYK Medical College Rahim Yar Khan.
2. Shahida Islam Medical & Dental College, Lodhran.
3. Al-Tibri Medical College, Karachi.
4. CMH Institute of Medical Sciences, Bahawalpur.

Originally Received: 1 March 2024

Revised: 11 April 2024

Accepted: 13 April 2024

Correspondence to:

Dr. Raja Faisal

RYK Medical College Rahim Yar Khan.

Department of Anatomy.

rajafaisal76@hotmail.com

Introduction:

Senile cataracts have been identified as one of the commonest cause of visual disturbance and even complete blindness all over the world.¹ Throughout the life eye lens function needs an intact refractive index, biomechanical integrity and transparency.² While axial length is generally thought to be the main biometric factor that influences refractive growth, it is also believed that the crystalline lens plays an important part in the emmetropization of the human eye.³ The lens is one of the most important components of vision and plays an essential role in the adjustment of vision for both near and far as well as in the adaptation of vision in dark and bright environments is crucial for vision.⁴ Cataract formation is a degenerative alteration of the lens metabolism. There is a variety of biochemical changes involved in the

formation of a cataract.⁵ Cataract formation is accelerated by hyperglycemia due to the excessive production of oxidative stress.⁶ A cataract is a discolored or clouded lens. It has several underlying causes and is usually associated with a decrease in optical quality due to a decrease in lens clarity and a change in lens color.⁷ Cataracts are most common among middle-aged and older people (>40 years) and the risk of developing them increases with age. Signs and symptoms of a cataract include lens loss, painless vision, blurred vision, and other visual problems that affect both eyes.⁸ Many people with other systemic diseases have a higher risk of developing a cataract, such as; cardiovascular disease patients.⁹ Cataracts are the leading cause of blindness worldwide. It also causes moderate-severe vision impairment around the world.¹⁰ Senile Cataracts (Age-related Cataract) affects about 17% of the world's population and causes more than half of vision loss and significant disease and economic burden worldwide.¹¹

Materials and Methods:

Forty-two (42) patients having senile cataracts who underwent surgery in Sheikh Zayed Hospital over six (6) Months from January 2022 to June 2022, were included. Patients between 55-70 years with senile cataracts were included. Patients with any systemic disease e.g. hepatitis, myocardial infarction, diabetes mellitus, hypertension, or glaucoma, and any history of ocular trauma were excluded.

Twenty-five (25) patients were operated on for intra-capsular cataract-containing lens removal at the ophthalmology department of Sheikh Zayed Hospital Rahim Yar Khan and in addition also donated three (3) lenses as control which were obtained from patients (who fell victim of evisceration) to support our study. Twenty-five (25) senile intra-capsular cataracts were obtained from the Eye Theatre of Sheikh Zayed Hospital Rahim Yar Khan and were processed at once to prevent any histopathological/morphological change.

All the lenses (control, close to normal or with cataract) were fixated in 10% buffered neutral formalin for 24 hours¹², later cut into equal halves, and fixed in fresh fixative for an additional 30 hours. Then lens tissues were gradually dehydrated in increasing concentration of alcohol from 60% to 100%. Lens Tissues were bathed by xylene and embedded in paraffin. Sections of Three (3) micron were cut by the help of a microtome and for visual accuracy were stained using hematoxylin and eosin H&E and periodic acid Schiff (PAS) stains. Finally, lenses were put under the microscope for histopathological and morphological analysis, particularly focusing on alterations in the capsule, lining surface epithelium, arrangement of fibers, and nucleus of the lens.

Results:

The lenses used as the control presented a normal appearance on thorough observations. They showed absolute transparency, no evidence of angiogenesis, were delicately soft, elasticity was observed and in shape, bi-convexity was observed, and a comparatively flat anterior surface was also observed, all the surfaces were smooth and had an average diameter of 8mm and thickness of 3-4 mm. Lenses with senile cataracts showed opaque yellow to light brownish color, consistency was rigid, had irregular surfaces, and violated diameters.

Figure 1 shows that in transverse sections, the control lens was biconvex, the body surrounded by hardened capsule (A) with the nucleus of the lens placed centrally, separated from behind by posterior capsule covering, while ventrally and at thickest point by sub-capsular single-layered sheet of lining epithelial units, also aligned with ventral cortex which is made up of parallel and meridionally placed layers of lens fibers whose nuclei showed the arched placement named as bow arrangement (B) with elongated nuclei (C)

Insignificant thinning in lens capsule was evident in lenses affected by cataracts in all

planes in comparison to control lenses (Table 1). A significant decrease was observed in the mean diameter of sub-capsular mono-layered flattened epithelial cells ($9.05 \pm 0.42 \mu\text{m}$) (p -value < 0.05) in cataract-affected lenses in comparison to control lenses with a value of ($12.08 \pm 0.86 \mu\text{m}$).


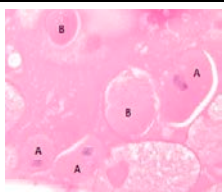
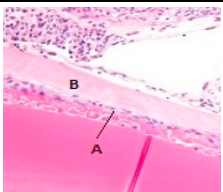
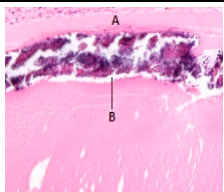
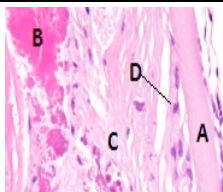
Quality bow arrangement and original lamellar organization of the lens vanished in the cortex of lenses affected by senile cataracts. Many other pathological changes were evident in histopathological slides of cataract-affected lenses (Table 2).

Table 1: Comparative Analysis of thickness of the capsule (μm) and lining epithelial cell span (μm) in control vs cataract-containing lenses.

Capsular regions and cells (μm)	Control (μm)	Cataractous lenses (μm)	P value
Equatorial capsule	5.18 ± 0.61	5.21 ± 0.41	>0.05
Posterior capsule	4.50 ± 0.76	2.38 ± 0.38	>0.05
Anterior capsule	7.02 ± 0.85	5.99 ± 0.88	>0.05
Lining epithelia	12.01 ± 0.86	9.05 ± 0.42	<0.05

Table 2: Histopathological variations in 20 human senile cataract-affected lenses in percentage. (Many lenses possess more than one change)

Histopathologic Variation	No of lenses	altered morphology %	Patients age (years)	Patients mean age (years)
Villi in the posterior capsule	3	15	65-70	68
Calcification in lens	11	55	60-70	66
Ectopic epithelia	4	20	65-70	67
Nuclear fibrosis	8	40	60-70	67
Enlarged or bladder cell	9	45	55-67	61

				
Figure-1 Transverse histological section of the control lens.	Figure-2 Bloated lens fibers with pathologically retained nucleus are known as balloon cells (A). Morgagnian globules (B) are roundly shaped, bloated fibers. (H&E stain $\times 400$, $3\mu\text{m}$)	Figure-3 Subcapsular <u>hyperplasia</u> of the epithelium just under the anterior <u>lens capsule</u> (A). The cataract-affected lens exhibits thickening and of the <u>anterior lens capsule</u> (B) (H&E stain $\times 400$, $3\mu\text{m}$)	Figure-4 (A) Anterior capsule of the lens. subcapsular deposits of the calcium just under the anterior capsule of the lens (B). (H&E stain $\times 400$, $3\mu\text{m}$)	Figure-5 Anterior capsule of the lens (A), fragmented, condensed lens fiber material (B), Subcapsular fibrosis (C) and also note hyperplasia of <u>epithelium</u> just under the anterior capsule (D). (H&E stain $\times 400$, $3\mu\text{m}$)

Discussion:

In our study we found that lens thickness does not change in senile cataracts and similar findings were reported by Lopez and Diez in their study.¹³ A significant decrease of $0.905 \pm 0.42 \mu\text{m}$ was observed in the mean epithelial cells of fourteen (14) cataract-affected lenses range (6 to $10 \mu\text{m}$) when analyzed with similarly aged lenses of normal people having a value of $12.01 \pm 0.86 \mu\text{m}$ (range 10 to $14 \mu\text{m}$). Identical remarks were presented by Xie et al while studying apoptosis of lens epithelial cells and the possible cause of this change stated by him was decreased metabolic activity in cataract-affected lenses.¹⁴ Balloon cell finding may be related to decreasing metabolic activity with progressing age, Li et al in their work on differently expressed genes associated with deficient lens epithelial cells mentioned similar findings and suggested increasing oxidative stress related to age might be a factor responsible for this via up and down-regulation of certain genes.¹⁵ Finding of Nuclear fibrosis was frequently observed in a significant number of cases, denaturation and coagulation of soluble lens protein could be a potential reason for this pathology, Taiyab et al in their study regarding Understanding the Role of Yes-Associated Protein reported similar findings and concluded that change occurred in Fibrotic cataracts, posterior capsular opacification (PCO), and anterior subcapsular cataracts (ASC) are mainly attributed to the transforming growth factor- β (TGF β)-induced epithelial-to-mesenchymal transition (EMT) of lens epithelial cells (LECs).¹⁶ While evaluating the calcium deposition on cataract affected lens, it is assumed that a potential reason for this is associated with increased permeability of the lens caused by sluggish metabolism and low energy as a result of increasing age. Chowdhary et al were on the same page as us on the similar finding but in addition, they indicated yet another possible mechanism of Activation of Nrf2/HO-1 Antioxidant Pathway by heme

Attenuates.¹⁷ We found that a significant number of cataract-affected lenses showed the dorsal movement of epithelial cells under the posterior capsule, but we are unaware of the possible pathologic mechanism behind it, mirrored findings had been recorded in a study by Li et al also argued that possibly Arginase-1 promotes lens epithelial-to-mesenchymal transition in different models of anterior subcapsular cataract.¹⁸ Many of the cataract-affected lenses showed more than one pathologic finding. Many of these changes were possibly due to genetic modifications as stated by Kafeel S in 2022.¹⁹ Our study concludes that lack of energy required for normal physiological function of lens with increasing age may be the best assumed reason behind sclerotic and degenerative pathologies of lenses.

Conclusion:

Most of the lenses attributed more than one histopathological finding. A marked decrease in the size of epithelial cells was observed, whereas alterations in the thickness of the lenses were insignificant with a p-value of >0.05 .

References:

1. Luo J, Chen X, Yang Y, Liu Y, Feng Y, Chen G. Association of MTHFR C667T Polymorphism, Homocysteine, and B Vitamins with Senile Cataract. *J Nutr Sci Vitaminol (Tokyo)*. 2023;69(2):136-144. doi: 10.3177/jnsv.69.136. PMID: 37121723.
2. Cheng C, Parreno J, Nowak RB, Biswas SK, Wang K, Hoshino M, Uesugi K, Yagi N, Moncaster JA, Lo WK, Pierscionek B, Fowler VM. Age-related changes in eye lens biomechanics, morphology, refractive index and transparency. *Aging (Albany NY)*. 2019 Dec 16;11(24):12497-12531. doi: 10.18632/aging.102584. Epub 2019 Dec 16. PMID: 31844034; PMCID: PMC6949082.

3. Chakraborty R, Lacy KD, Tan CC, Park HN, Pardue MT. Refractive index measurement of the mouse crystalline lens using optical coherence tomography. *Exp Eye Res.* 2014 Aug;125:62-70. doi: 10.1016/j.exer.2014.05.015. Epub 2014 Jun 2. PMID: 24939747; PMCID: PMC4121730.
4. Shaheen G, Paul J, Fleischman D. Macrophakia: The characterization of a novel lens condition. *Heliyon.* 2024 Jan 26;10(3):e25161. doi: 10.1016/j.heliyon.2024.e25161. PMID: 38322959; PMCID: PMC10844534.
5. Hegde KR, Henein MG, Varma SD. Establishment of mouse as an animal model for study of diabetic cataracts: biochemical studies. *Diabetes Obes Metab.* 2003 Mar;5(2):113-9. doi: 10.1046/j.1463-1326.2003.00251.x. PMID: 12630936.
6. Kafeel S, Hashim Z, Fawwad A, Nawab SN. Predisposition of SOD1, GPX1, CAT genetic variants and their haplotypes in cataractogenesis of type 2 diabetes mellitus in Pakistan. *Acta Diabetol.* 2022 May;59(5):623-632. doi: 10.1007/s00592-021-01832-5. Epub 2022 Jan 17. PMID: 35037135.
7. He L, Cui Y, Tang X, He S, Yao X, Huang Q, Lei H, Li H, Liao X. Changes in visual function and quality of life in patients with senile cataract following phacoemulsification. *Ann Palliat Med.* 2020 Nov;9(6):3802-3809. doi: 10.21037/apm-20-1709. Epub 2020 Nov 5. PMID: 33183034.
8. Olson RJ, Braga-Mele R, Chen SH, et al. Cataract in the Adult Eye Preferred Practice Pattern®. *Ophthalmology* 2017;124:1-119.
9. Osmanov EM, Manyakov RR, Velichko PB, Zhabina UV, Fabrikantov OL, Nikolashin SI. Rasprostranennost' i vyyavlyaemost' vozrastnoi katarakty pri zbolevaniyakh serdechno-sosudistoi sistemy [Prevalence and detection rate of senile cataract in individuals with cardiovascular diseases]. *Vestn Oftalmol.* 2022;138(4):41-47. Russian. doi: 10.17116/oftalma202213804141. PMID: 36004590.
10. Rewri P, Lohan A, Aggarwal S, Chodhary P, Singhal A. Cataract surgical reach: Falling short to catch white cataracts! *Indian J Ophthalmol.* 2021 Jun;69(6):1575-1578. doi: 10.4103/ijo.IJO_2560_20. PMID: 34011744; PMCID: PMC8302299.
11. Yuan S, Wolk A, Larsson SC. Metabolic and lifestyle factors in relation to senile cataract: a Mendelian randomization study. *Sci Rep.* 2022 Jan 10;12(1):409. doi: 10.1038/s41598-021-04515-x. PMID: 35013517; PMCID: PMC8748724.
12. Lee, G. and Luna, H.T. Manual of histologic staining methods of the Armed Forces Institute of Pathology, 3rd edition. New York, Toronto. London and Sydney. McGraw Hill Book Company, 1968.
13. López-de la Rosa, A., Díez-Montero, C., Martínez-Plaza, E. *et al.* Senile Cataract Formation Does Not Affect Crystalline Lens Thickness. *Ophthalmol Ther* 13, 819–830 (2024).
14. Xie Q., Xue L., Cao X., Huang L., Song Y. (2022). Apoptosis of lens epithelial cells and expression of NLRP3-related proteins in patients with diabetes and cataract. *Ocular Immunol. Inflamm.*, 1–8. 10.1080/09273948.2022.2079537.
15. Li H, Gao L, Du J, Ma T, Ye Z, Li Z. Differentially expressed gene profiles and associated ceRNA network in ATG7-Deficient lens epithelial cells under oxidative stress. *Front Genet.* 2022 Dec 7;13:1088943. doi: 10.3389/fgene.2022.1088943. PMID: 36568386; PMCID: PMC9768497.
16. Taiyab A, Belahlou Y, Wong V, Pandi S, Shekhar M, Chidambaranathan GP, West-Mays J. Understanding the Role of Yes-Associated Protein (YAP) Signaling in the Transformation of Lens Epithelial Cells (EMT) and Fibrosis. *Biomolecules.* 2023 Dec

- 9;13(12):1767. doi: 10.3390/biom13121767. PMID: 38136638; PMCID: PMC10741558.
17. Chowdhury A, Balogh E, Ababneh H, Tóth A, Jeney V. Activation of Nrf2/HO-1 Antioxidant Pathway by Heme Attenuates Calcification of Human Lens Epithelial Cells. *Pharmaceuticals (Basel)*. 2022 Apr 19;15(5):493. doi: 10.3390/ph15050493. PMID: 35631320; PMCID: PMC9145770.
18. Li Q, Wang Y, Shi L, Wang Q, Yang G, Deng L, Tian Y, Hua X, Yuan X. Arginase-1 promotes lens epithelial-to-mesenchymal transition in different models of anterior subcapsular cataract. *Cell Commun Signal*. 2023 Sep 18;21(1):236. doi: 10.1186/s12964-023-01210-4. PMID: 37723490; PMCID: PMC10506332.
19. Kafeel S, Fawwad A, Basit A, Nawab SN. Clinical Association of Biochemical Variations Among Multilocus Genotypes of Antioxidant Enzymes with Susceptibility of Cataract in Hyperglycemia. *Appl Biochem Biotechnol*. 2022 Sep;194(9):3871-3889. doi: 10.1007/s12010-022-03957-x. Epub 2022 May 12. PMID: 35556207.

Authors Contribution

Concept and Design: Dr. Raja Faisal Zulfiqar
Data Collection / Assembly: Umair Tariq Mirza, Fatima Akbar Shah
Drafting: Dr Adeel Zafar, Dr Zen-ul-Abideen
Statistical expertise: Dr. Syed Liaquat Ali
Critical Revision: Dr Yousuf Khoso, Dr Raja Faisal Zulfiqar