



ISSN 3006-2543 (Online)

ISSN 1990-3863 (Print)

AL-SHIFA JOURNAL OF OPHTHALMOLOGY

An Open Access, Peer Reviewed, Quarterly Journal of
AL-SHIFA TRUST EYE HOSPITAL

Vol. 21, No. 2, April – June 2025

Indexed in

Index Medicus- EMR
Asian Digital Library
Pak Medinet

Recognized by

Higher Education Commission (HEC), Pakistan
College of Surgeon and Physician (CPSP), Pakistan
Pakistan Medical and Dental Council (PMDC) IP/033

ISSN 3006-2543 (Online)
ISSN 1990-3863(Print)

A
S
J
O

Al-Shifa Journal of Ophthalmology

Vol. 21, No. 2, April – June 2025

QUARTERLY PUBLISHED

- **Editorial: Intravitreal vs Sub-Tenon Triamcinolone in DME**
- **Vitamin D Levels and Myopia in Children**
- **Three-Point Local Anesthesia for Ex-DCR**
- **Intracameral Lidocaine in Sutureless Cataract Surgery**
- **Aqueous Misdirection in Post-Trabeculectomy**
- **Academic Performance in Medical Students with Eye Disease**
- **Corneal Epithelial Changes Post-PRK**
- **Risk Factors for PRP Sessions in Diabetic Retinopathy**
- **Retinal Inner Layer Disorganization in Diabetes**
- **Heparinised Irrigation and Inflammation in Phacoemulsification**

Abstracts available at <https://www.asjoalshifaeye.org> and <https://www.pakmedinet.com/ASJO>
Manuscript submission through online platform ejmanager.com

Indexed in Index Medicus -EMR, Asian Digital Library (ADL)
Recognized by Higher Education Commission (HEC), Pakistan
Recognized by College of Surgeon and Physician (CPSP), Pakistan
Recognized by Pakistan Medical and Dental Council (PMDC) IP/003

Al-Shifa Journal of Ophthalmology

Editorial inquiries should be addressed to Prof. Dr. Tayyab Afghani, Department of Orbit and Oculoplastics, Al-Shifa Trust Eye Hospital, Jhelum Road Rawalpindi, Pakistan.
Tel: 0092 51 5487821-25, Fax: 0092 51 5487827; Email: aqrpio@yahoo.com ;
Website: www.asjoalshifaeye.org

| | |
|--|------------|
| Editorial: Gene Therapy in Ophthalmology: The Future of Inherited Retinal Diseases | 62 |
| Mehmona Asgher | |
| Comparative Efficacy Of Intravitreal versus Posterior Sub-Tenon Triamcinolone Acetonide Injections For Diabetic Macular Edema | 63 |
| Mahwish Shahid, Anum Nadir, Fauzia Naureen, Uzma Rehman, Alizay Gohar, Summaya Anjum | |
| Effective Way Of Local Anesthesia For External Dacryocystorhinostomy (Ex-Der); A Three Point Infiltrative Local Anesthesia | 70 |
| Piya Muhammad Musammat Rafi, Muhammad Rizwan Khan, Shehzad Manzoor, Muhammad Jahan Zaib Khan, Sarfraz Ahmad Mukhtar, Asif Manzoor | |
| Correlation of vitamin D levels with Myopia in Children: A Cross-Sectional Survey at a Tertiary Care Hospital in Rawalpindi | 76 |
| Saba Afzal Shaikh, Nazia Mushtaq, Nyla Gill, Khadija Mohammad, Ayyaz Hussain Awan, Ayesha Tariq | |
| Intracameral Lidocaine: A Safe and Effective Anesthetic Option for Manual Sutureless Cataract Surgery | 82 |
| Qaim Ali Khan, Muhammad Usman Arshad Qureshi, Rabia Sharif Bhatti, Aunaza Maqbool, Yasir Iqbal Malik | |
| Aqueous Misdirection Syndrome in Post-trabeculectomy Patients | 89 |
| Rima Khan, Yousaf Jamal Mahsood | |
| Histological/pathological Evaluation of Post Photo-Refractive-Keratectomy (PRK) Induced Changes in Corneal Epithelial Thickness and its Impact on Physiological Eye Functions | 97 |
| Raja Faisal Zulfiqar, Muhammad Yousuf Khoso, Tayyaba Kazmi, Sadia Sundus, Irfan Ul Akba, Raheela Adil | |
| Association of Age Groups, Gender, Smoking, and Hypertension with Pan-Retinal Photocoagulation Sessions in Diabetic Retinopathy Patients in the Population of D.I. Khan | 108 |
| Muhammad Shoaib Khan, Muhammad Kamran Khalid, Muhammad Sharjeel, Muhammad Abdullah, Hidayatullah Mahsud | |
| Disorganization of Retinal Inner layers in Diabetic Patients | 113 |
| Nimra Akram, Mazhar Ul Hassan | |
| Effect of Peroperative Use of Heparinised Irrigating Solution on Postoperative Inflammation in Phacoemulsification | 121 |
| Erum Nasir, Intisar Ul Haq Rana, Sana Nadeem, Asfandyar Asghar, Naila Obaid, Tehmina Nazi | |

Effective Way Of Local Anesthesia For External Dacryocystorhinostomy (Ex-Dcr); A Three Point Infiltrative Local Anesthesia

Piya Muhammad Musammat Rafi¹, Muhammad Rizwan Khan², Shehzad Manzoor³, Muhammad Jahan Zaib Khan³, Sarfraz Ahmad Mukhtar³, Asif Manzoor⁴

Abstract:

Objectives: To document and illustrate the pain-free method for external dacryocystorhinostomy (Ex-DCR) under 3-point infiltrative local anesthesia.

Methods: A total of 30 patients were operated on by the new local anesthesia technique after approval from the institutional Review Board of the Bahawalpur Victoria Hospital, Bahawalpur. Patients between 20 and 70 years of age and of any sex were included in the study. SPSS was used for analyses. A Verbal Rating Scale (VRS) was used in our study for pain scoring as described by the patient.

Results: Among the patients, 12(40%) were males and 18(60%) were females with a mean age of 53.73 ± 13.128 years. During the skin incision, 25(83.3%) patients described no pain, while 5(16.7%) had only discomfort. While elevating the periosteum, only 10(33.3%) patients felt discomfort. During Ostium Creation, 15 (50%) patients felt discomfort, and 2 (6.7%) felt distressed. 8(26.7%) participants felt discomfort at Flap Creation and Wound Closure, and it was pain-free for 25(83.3%). Only 8(26.7%) felt discomfort 2 hours post-operatively. A weak correlation was observed when using Pearson's Correlation.

Conclusion: Our three-point local anesthesia technique is highly effective for External Dacryocystorhinostomy. It eliminates the need for general anesthesia in carefully selected patients. Even without intravenous sedation, the procedure was completed successfully with high patient comfort and acceptability. The technique is easy and can be employed when local anesthesia is selected for patients undergoing External Dacryocystorhinostomy. *Al-Shifa Journal of Ophthalmology* 2025; 21(2): 70-75. © Al-Shifa Trust Eye Hospital, Rawalpindi, Pakistan.

1. *Institute of Ophthalmology and Allied Vision Sciences, Nishtar Medical University Multan.*
2. *Faisalabad Medical University and Allied Hospitals, Faisalabad.*
3. *Quaid e Azam Medical College, Bahawalpur.*
4. *Bakhtawar Amin Medical College Multan.*

Institute of Ophthalmology and Allied Vision Sciences, Nishtar Medical University Multan.
drmusammat@gmail.com

Introduction:

The Lacrimal outflow pathway starts from the puncta and ends at the nasolacrimal duct in the nose. Blockage along this tear flow passage results in an overflow of tears, known as epiphora, which can be congenital or acquired. Acquired nasolacrimal duct obstruction is a common cause of epiphora in the adult population. Mostly, it is idiopathic. Treatment for nasolacrimal duct obstruction is a surgical procedure known as external dacryocystorhinostomy (Ex-DCR).¹ In our

Originally Received: 10 Jan 2025

Revised: 27 Jan 2025

Accepted: 10 Feb 2025

Correspondence to:

Piya Muhammad Musammat Rafi

study population, Dacryocystitis (an inflammation of the nasolacrimal sac, which is frequently caused by infection or the obstruction of the nasolacrimal duct) is a common presentation. DCR is a commonly used surgical procedure for managing epiphora due to obstruction of the nasolacrimal duct.² It is a bypass procedure to create an anastomosis between the lacrimal sac and the nasal mucosa via a bony ostium.

A new passage for tear flow can be created either through the external approach through skin incision or by internal approach. External dacryocystorhinostomy remains the gold standard for the management of chronic dacryocystitis. It has a high success rate of 85% to 99%.^{2,3} The internal approach of Endoscopic / endonasal dacryocystorhinostomy (Endo-DCR) has the advantages of decreased morbidity, decreased post-operative, and reduced recovery time.⁴ Previously, the majority of Ex-DCRs were being done under general anesthesia (GA). Nowadays, there has been a shift to Local Anesthesia (LA) because of improved techniques and knowledge about anesthesia. LA requires less ancillary and specialized staff and a shorter hospital stay. Topical and Local Infiltrative anesthetics are the most commonly used form of ocular anesthesia, used in both an office and surgical setting, and carry a minimal side effect profile. In Ex-DCR, bone cracking showed the highest levels of pain experienced during surgery in local anesthesia^{5,6}.

Effective local anesthesia determines the success and acceptance of the procedure for the patient. Different techniques are employed for local anesthesia for Ex-DCR; single prick and multiple point prick anesthesia is used by many surgeons for Ex-DCR.^{7,8} Keeping in mind the need for and importance of local anesthesia for this frequently performed procedure, we devised a technique to deploy local anesthesia to numb all nerve supply to this area. Our 3-point infiltrative anesthesia technique encompasses the whole surgical

field for comfortable surgery, including the deep osteotomy pain. Our pain verbal score, as the patients narrated, depicted the usefulness of the technique.

Methods:

For this noncomparative, interventional case series study, Data were collected prospectively of all patients who fulfilled the inclusion criteria and underwent admission in the Eye ward of the Bahawal Victoria Hospital (BVH), Bahawalpur, a tertiary healthcare facility in the region. The study duration was from July 2024 to December 2024. Non-probability consecutive sampling technique was used. A total of 30 patients were operated on by this new, painless local anesthesia technique. Patients with recurrent dacryocystitis, chronic mucoid reflux, painful distention of the lacrimal sac, and bothersome epiphora were included in the study, and patients with Acute dacryocystitis, Malignant lacrimal sac tumor, intranasal tumor or polyp, turbinate impaction, deviated septum, or chronic allergic rhinitis were excluded from the study. Informed consents were taken from every patient, and the procedure was fully explained. The study was approved by the Institutional Review Board, QAMC, BVH, Bahawalpur. Patients between 20 and 70 years of age and of any sex were included in the study. SPSS was used for analyses. Standard surgical techniques were followed for External Dacryocystorhinostomy and performed under the new technique of local anesthesia by a single consultant eye surgeon having expertise in this technique. A 5ml mixture of Lignocaine 2% and equal volumes of bupivacaine 0.5% mixed with 1:100,000 epinephrine was injected into the subcutaneous tissue and periosteum at the planned incision site. Xylometazoline hydrochloride nasal solution. 1:1000 was used as a nasal spray for decongestion. Nasal packing was done by soaking the gauze in Xylocaine gel. The solution was injected at three points: above the medial end of the medial canthal tendon, below the

tendon, and sliding along the anterior lacrimal crest, keeping in mind the nerve supply in the region (as shown in pictures). Surgery started ten minutes after the local anesthesia injection.

A Verbal Rating Scale (VRS) was used in our study for pain scoring as described by the patient. Pain at different stages was scored as: no pain=0, discomfort=1, distressing=2, intense=3. Excruciating unbearable=4. Pain was scored at different stages of surgery like Skin incision, periosteum elevation, Ostium creation, flap creation, wound closure and 2 hours postoperatively.

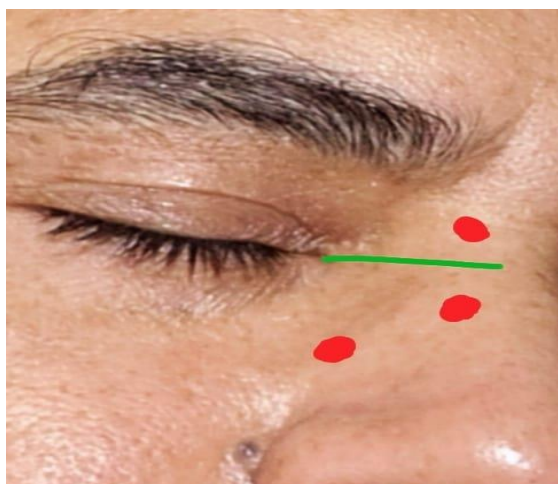


Figure 1: Injection sites

Note: green line is landmark from medial canthus to nasal bridge. Red points show our three points of local anesthesia.

Results:

A total of 30 patients were operated on under the new technique of local anesthesia. Among the patients, 12(40%) were male and 18(60%) were female. The mean age of the patients was 53.73 ± 13.128 years. Pain level was assessed at predesigned steps of surgery. At Skin Incision; 25(83.3%) patients observe no pain, while 5(16.7%) had only discomfort. While elevating the periosteum, only 10(33.3%) patients felt discomfort. During Ostium Creation, 15 (50%) patients felt

discomfort, and 2 (6.7%) felt distressed. 8(26.7%) participants felt discomfort at Flap Creation and Wound Closure, and it was pain-free for 25(83.3%). Only 8(26.7%) felt discomfort 2 hours post-operatively. In our anesthesia technique, no patient felt Intense, excruciating, or Unbearable pain. Surgery was completed on all patients, and no case was postponed or aborted. Intravenous sedation was not used in any patient. Table 1 and 2.

Pearson's Correlation was used for the association of pain with patient age and gender. At Skin incision, a weak correlation between patient gender and pain was found (p value .317, Pearson's r .183) for this small sample size. The same was observed for the age of the patient (p=.282, Pearson's r .002). During Periosteum elevation, no significant correlation was observed between patient gender and level of pain (p=.114, Pearson's r .289), and for age (p value .363). During Ostium creation; the relationship for pain and gender is weak (p=.116), on the other hand statistics for pain and age of the patient during this step of surgery are p=.171, Pearson's r -.457. At Flap creation, no relationship of pain was present with the gender of the patient, but a relationship was found for the age of the patient and the pain during this step of surgery (p=.245, Pearson's r -.232). Patients of younger age felt more discomfort. Wound closure was pain-free for age and gender. While 2 Hours Post-Operatively, a weak relationship exists for age and gender of the participants and pain during surgery (Pearson's r -.402). Overall female patients and younger age patients showed low pain threshold. But results are not significant (p-value more than 0.05) because sample size was small. Larger sample size is needed to establish the significant relationship between pain and gender/age of the patients. Overall, 70% of patients felt no pain during any stage of surgery. Others felt mild Discomfort, and only 2 patients (N=30) felt distressing pain during osteotomy.

Table 1: Patients Age and Gender

| Patient Age in Years. N=30 | Mean | Median | Std. Deviation | Minimum | Maximum |
|-------------------------------|----------------|-----------|----------------|---------|---------|
| | 53.73 | 57.00 | 13.128 | 21 | 70 |
| Patient Gender N=30 | Male Female | Frequency | Percent | | |
| | | 12 | 40.0 | | |
| | | 18 | 60.0 | | |

Table 2: Verbal Rating Scale for Pain

| Steps of surgery | Pain Scale | Frequency | Percent |
|----------------------|-------------|-----------|---------|
| Skin incision | No Pain | 25 | 83.3% |
| | Discomfort | 5 | 16.7% |
| Periosteum Elevation | No Pain | 20 | 66.7% |
| | Discomfort | 10 | 33.3% |
| Ostium creation | No Pain | 13 | 43.3% |
| | Discomfort | 15 | 50% |
| | Distressing | 2 | 6.7% |
| Flap Creation | No Pain | 21 | 70% |
| | Discomfort | 8 | 26.7% |
| | Distressing | 1 | 3.3% |
| Wound Closure | No Pain | 25 | 83.3% |
| | Discomfort | 5 | 16.7% |
| 2Hours PostOp | No Pain | 22 | 73.3% |
| | Discomfort | 8 | 26.7% |

Discussion:

Ex-DCR is being performed both under general anesthesia as well as local anesthesia. A trend for local anesthesia is gaining popularity because of its comfort, cost-effectiveness, and without the complications of general anesthesia. Further, Ex-DCR under Local anesthesia is successful whether it is done with sedation or without sedation, as many surgeons routinely do not use intravenous sedation.^{9,10} In our study, we explored and elaborated an innovative way for local anesthesia. Among 30 participants, in our study female patients outnumbered the male patients. This trend is also seen in previous studies. Females are more prone to nasolacrimal duct obstruction than males because of anatomy (angulation) of nasolacrimal duct and hormonal changes.²

Detailed knowledge of nerve supply in the surgical field and periorbital area is required for proper infiltrative local anesthesia. The lacrimal sac area is mainly supplied by the Supra-trochlear and Infra-trochlear nerves and branches from the infraorbital nerve and external nasal nerves. There is also an overlap of the periorbital sensory innervation to this area.^{11,12,14} Our three-point infiltrative anesthesia technique covers the main nerve supply in this area as well as overlapping areas. Nasal mucosal anesthesia was achieved (by nasal packing) using the combined application of Xylometazoline hydrochloride nasal solution. 1:1000, as nasal spray, and 2% xylocaine gel on ribbon gauze¹³. With the evolving technique of endoscopic endonasal dacryocystorhinostomy, effective local anesthesia techniques have become more important. Sometimes

combined approach, Endoscopic and External Dacryocystorhinostomy, is needed when there is nasal pathology as well.^{15,16}

In previous studies, Patients reported good surgical experience¹⁷ for external Dacryocystorhinostomy under local anesthesia. In our technique, overall, 70% of patients observed no pain, 23% had discomfort and only 7% felt distressed during surgery. No patient felt intense, excruciating, or unbearable pain. Previously, many authors reported successful outcomes, and even comparative studies showed that patients operated on under local and general anesthesia had similar outcomes.^{18,19,20} We used a modified Verbal Rating Scale (VRS) to document pain as observed by the patient during surgery and 2 hours post-op. All surgeries were completed successfully, with high patient confidence and comfort. In the future, large sample sizes and comparative studies will be required to explore the techniques of local anesthesia.

Conclusion:

Our three-point local anesthesia technique is highly effective for External Dacryocystorhinostomy. It eliminates the need for general anesthesia in carefully selected patients. Even without intravenous sedation, the procedure was completed successfully with high patient comfort and acceptability. The technique is easy and can be employed when local anesthesia is selected for patients undergoing External Dacryocystorhinostomy.

References:

1. Iqbal U, Ali F, Malik IQ, Zahoor S, Waqas HAR. Surgical Outcomes of External Dacryocystorhinostomy under Local Anaesthesia in a Tertiary Care Hospital: a Prospective Cohort Study. *Ann King Edward Med Uni Apr - Jun 2021*; 27(2):228-33
2. Khalid M, Rizwan M, Nawaz Khan MI. Comparison of Severity of Pain with and Without Sedation in Patients Undergoing External Dacryocystorhinostomy under Local Anesthesia. *P J M H S. OCT – DEC 2015*; 9(4).
3. Khan QA, Zia S, Iqbal Y. External Dacryocystorhinostomy under Local Anesthesia. *Pak J Ophthalmol.* 2016; 32(1).
4. Aslam MA, Mirza AB, Butt IA. Results of endo-scope endonasal dacrocystorhinostomy. *JPMMA.* 2014; 64(6):619.
5. Pucchio A, Pur DR, Dhawan A, Sodhi SK, Pereira A, Choudhry N. Anesthesia for ophthalmic surgery: an educational review. *Int Ophthalmol.* 2023 May;43(5):1761-1769. doi: 10.1007/s10792-022-02564-3.
6. Knezevic MM. Stojkovic M S. Vlajkovic GP. Jovanovic MB. Rasic DM. Pain during external dacryocystorhinostomy with local anesthesia. *Med SciMonit.* 2011;17(6):341-46.
7. Maheshwari R. Single-prick infiltration anesthesia for external dacryocystorhinostomy. *Orbit.* 2008;27(2):79-82. doi: 10.1080/01676830701377229
8. Sahaf IA. DCR Local anesthesia (A new technique). *Ann King Edward Med Uni Jan - Mar 2004*;10(1):17-8
9. Ciftci F, Pocan S, Karadayi K, Gulecek O. Local versus general anesthesia for external dacryocystorhinostomy in young patients. *Ophthalmic Plast Reconstr Surg.* 2005 May;21(3):201-6. doi:10.1097/01.iop.0000163317.73873.c9
10. Aytogan H, Doran MA, Ayintap E. Outcomes of External Dacryocystorhinostomy under General and Local Anesthetics in a Tertiary Clinic. *Beyoglu Eye J.* 2022 Feb 18;7(1):25-29. doi: 10.14744/bej.2021.95967

11. Leatherbarrow B. Oculoplastic Surgery. 2ed. UK: Informa Healthcare; 2011. chapter 2.
12. Tyers AG, Collin JRO. Colour atlas of ophthalmic plastic surgery. 4thed. UK: Elsevier; 2018. Chapter 4.
13. Tawfik HA, Youssef OR. Simplified local anesthesia technique for external dacryocystorhinostomy without nasal packing: a new technique and pilot study outcome. Clin Ophthalmol. 2013;7:2265-70. doi: 10.2147/OPTH.S53626.
14. Riad W, Chaudhry IA. Anaesthesia for dacryocystorhinostomy, Current Anaesthesia & Critical Care. 2010; 21(4): P 180-183.
15. Vinciguerra A, Resti AG, Rampi A, Bussi M, Bandello F, Trimarchi M. Endoscopic and external dacryocystorhinostomy: A therapeutic proposal for distal acquired lacrimal obstructions. Eur J Ophthalmol. 2023 May;33(3):1287-1293. doi: 10.1177/11206721221132746
16. Aslam S, Awan AH, Tayyab M. Endoscopic Dacrocystorhinostomy: A Pakistani Experience. Pak J Ophthalmol. 2010; 26: 2-6.
17. Putri CA, Tan JH. Ophthalmology service recovery with 'general anaesthesia to local anaesthesia conversion' or GALA initiative: a new surgical service pilot. BMJ Open Qual. 2023 Jan;12(1):e002083. doi: 10.1136/bmjopen-2022-002083.
18. Sagiv O, Rosen N, Priel A, Rosner M, Ben Simon GJ. Dacryocystorhinostomy (DCR) under local anesthesia. Harefuah. 2015 Feb;154(2):110-3, 136, 135.
19. Knežević MM, Vlajković GP, Stojković MŽ, Rašić DM, Stanković BR, Božić MM. Comparison of postoperative pain and satisfaction after dacryocystorhinostomy in patients operated on under local and general anesthesia. Med Sci Monit. 2012 May;18(5):CR265-70. doi: 10.12659/msm.882730.
20. McNab AA, Simmie RJ. Effectiveness of local anaesthesia for external dacryocystorhinostomy. Clin Exp Ophthalmol. 2002 Aug;30(4):270-2. doi: 10.1046/j.1442-9071.2002.00535.x

Authors Contribution

Concept and Design: Muhammad Rizwan Khan
 Data Collection / Assembly: Shehzad Manzoor
 Drafting: Muhammad Jahan Zaib Khan, Asif Manzoor
 Statistical expertise: Sarfraz Ahmad Mukhtar
 Critical Revision: Piya Muhammad Musammat Rafi