



**ASJO**

ISSN 3006-2543 (Online)

ISSN 1990-3863 (Print)

# AL-SHIFA JOURNAL OF OPHTHALMOLOGY

An Open Access, Peer Reviewed, Quarterly Journal of  
AL-SHIFA TRUST EYE HOSPITAL

**Vol. 22, No. 1, January - March 2026**

**Indexed in**

Index Medicus- EMR  
Asian Digital Library  
Pak Medinet

**Recognized by**

Higher Education Commission (HEC), Pakistan  
College of Surgeon and Physician (CPSP), Pakistan  
Pakistan Medical and Dental Council (PMDC) IP/033

ISSN 3006-2543 (Online)  
ISSN 1990-3863(Print)

A  
S  
J  
O

# Al-Shifa Journal of Ophthalmology

---

Vol. 22, No. 1, January - March 2026

---

QUARTERLY PUBLISHED

- **Editorial: The Myopia Tsunami: A Looming Public Health Crisis**
- **Effect of Pupil Dilatation on AL-Scan Biometry**
- **Contrast Sensitivity in  $\beta$ -Thalassemia Major**
- **Myopia Progression Across Age Groups**
- **High-Order Aberrations after Near Work in Myopic Students**
- **Eye Rubbing and Keratoconus Correlation**
- **Complications of Manual SICS Cataract Surgery**
- **Presbyopia Challenges in Free Eye Camps**

Abstracts available at <https://www.asjoalshifaeye.org> and <https://www.pakmedinet.com/ASJO>  
Manuscript submission through online platform [ejmanager.com](http://ejmanager.com)

---

**Indexed in Index Medicus -EMR, Asian Digital Library (ADL)**  
**Recognized by Higher Education Commission (HEC), Pakistan**  
**Recognized by College of Surgeon and Physician (CPSP), Pakistan**  
**Recognized by Pakistan Medical and Dental Council (PMDC) IP/033**

---

## Al-Shifa Journal of Ophthalmology

Editorial inquiries should be addressed to Prof. Dr. Tayyab Afghani, Department of Orbit and Oculoplastics, Al-Shifa Trust Eye Hospital, Jhelum Road Rawalpindi, Pakistan.  
Tel: 0092 51 5487821-25, Fax: 0092 51 5487827: Email: [drtayyabafghani@alshifaeye.org](mailto:drtayyabafghani@alshifaeye.org)  
Website: [www.asjoalshifaeye.org](http://www.asjoalshifaeye.org)

<b>Editorial: The Myopia Tsunami: A Looming Public Health Crisis</b> Saif Ullah	<b>7</b>
<b>Comparing Effect of Pre and Post Pupil Dilatation on Biometry Obtained by AL-Scan</b> Mehvash Hussain, Fizzah Farooq, Madiha Waseem	<b>9</b>
<b>Contrast Sensitivity in Patients with <math>\beta</math>-Thalassemia Major: A Cross-Sectional Study</b> Muhammad Asif, Asad Ullah, Fazal Noman, Safia Yaseen, Hafsa Sabir, Ahmad Jamal Khan	<b>17</b>
<b>Progression of Myopia Among Age Groups: A Retrospective Study</b> Iftikhar Ahmed, Zainab Hussain, Maaz Allah, Sarah Saleem, Rashid Hassan Alvi, Muhammad Nizamuddin	<b>23</b>
<b>Comparison of Changes in High Order Ocular Aberrations after Near Work in Myopic and Myopic Astigmatic University Students</b> Kashif Ullah Yousafzai, Muhammad Shaheer, Asima Rafique, Arooj Amjad, Muhammad Moin	<b>33</b>
<b>Correlation of Rubbing of Eyes with Keratoconus</b> Ayesha Bibi, Muhammad Affan, Muhammad Irfan Sadiq, Waqas Ali, Muhammad Usman Sadiq, Arooj Zahid	<b>42</b>
<b>Complications of Manual Small Incision Cataract Extraction Surgery</b> Shehroze Bin Masood, Shehla Khan, Muhammad Sajid Khan, Fahad Zafar Zafar, Sohaib Ali, Ehsan Sayyed, Masiha Shafee	<b>49</b>
<b>Unseen Challenges: Presbyopia in Free Eye Camp</b> Sadiqullah Khan, Siraj Safi, Sami Uddin, Zia Ullah, Muhammad Zahid Jadoon	<b>56</b>

# Complications of Manual Small Incision Cataract Extraction Surgery

Shehroze Bin Masood<sup>1</sup>, Shehla Khan<sup>1</sup>, Muhammad Sajid Khan<sup>1</sup>, Fahad Zafar Zafar<sup>1</sup>, Sohaib Ali<sup>2</sup>, Ehsan Sayyed<sup>3</sup>, Masiha Shafee<sup>4</sup>

## Abstract:

**Objective:** To determine the frequency and types of early complications following Manual small-incision cataract surgery (MSICS) among local population.

**Methods:** The study design was cross-sectional, conducted at Ophthalmology Department of Hayatabad Medical Complex, Peshawar, from September 2020 to 2021, including 135 patients undergoing cataract surgery, recruited using consecutive sampling technique. MSICS was performed under peribulbar anaesthesia. Demographic and clinical data were collected using a structured proforma. Post-operative complications, including increased intraocular pressure (IOP), hypotony, hyphema, and corneal decompensation, were assessed on the first post-op day. Data were analyzed using IBM SPSS version 27. Associations were evaluated using the Fisher Exact test, with  $p \leq 0.05$  considered statistically significant.

**Results:** The mean age of participants was  $56.5 \pm 5.3$  years, with 53.3% males and 46.7% females. Most surgeries were performed on the left eye (71.1%). Post-operative complications included IOP (8.1%), hypotony (3%), hyphema (3%), and corneal decompensation (3.7%). IOP was more frequent in patients aged 51-70 years (8.5%) and procedures lasting >20 minutes (11.8%). Hypotony and corneal decompensation were observed only in patients aged 51-70 years (3.4% and 4.3%, respectively) and procedures lasting >20 minutes (4.3% and 5.4%, respectively). Hyphema was more common in patients aged 35-50 years (5.6%) and procedures lasting >20 minutes (3.8%).

**Conclusion:** Manual small incision cataract surgery is a safe procedure with a low frequency of early postoperative complications. Surgeons should exercise care during surgery, especially in longer procedures, to minimize early complications. *Al-Shifa Journal of Ophthalmology* 2026; 22(1): 49-55.

1. Department of General Ophthalmology, Al Shifa Trust Eye Hospital, Kohat.
2. Department of Neurosurgery, Hayatabad Medical Complex, Peshawar.
3. Department of Anatomy, Khyber Medical College (KMC), Peshawar.
4. Khyber Medical University (KMU), Peshawar.

Originally Received: 15 Sep 2025

Revised: 27 Dec 2025

Accepted: 6 Feb 2026

## Correspondence to:

Shehroze Bin Masood  
Department of General Ophthalmology, Al Shifa Trust Eye Hospital, Kohat.  
shehrozebm@outlook.com

## Introduction:

A cataract is a cloudiness or opacity of the normally clear lens or its capsule (the transparent membrane around the lens) which makes it impossible for light to pass through the lens to the retina [1]. This completely sighted state may be experienced by a newborn, a grown-up or the elderly but is very common among the elderly. May be bilateral and may vary in intensity [2]. The condition is a gradual process, and at first it doesn't even cause any problems in everyday activities, but as the cataract grows, around the fourth or fifth decade, it will be completely cloudy, and interfere with normal activities [3]. Cataracts are leading cause of blindness in the world. The treatment options involve refractive glasses correction only in early

stage and surgery can be recommended in case of cataract development to a stage where it interferes with life, which is very beneficial [4].

In most countries, cataract surgery is the most common surgical procedure. With the advancement of the procedure and instruments, surgery is now much less risky than in the past, and has become the option of choice. However, the same benefits, such as more applications, less time consuming, shorter learning curve, and lower cost are equally available with MSICS. The high speed technique allows for MSICS to be done at high volume. Here we will examine various methodologies, safety and efficacy of MSICS, its development and use in the developing and poor countries [6]. There are extra anterior chamber manoeuvres to perform in MSICS such as capsulorrhexis, pushing the nucleus from the posterior chamber to the anterior, and removal of the nucleus from the scleral tunnel. The surgeon has to re-enter the eye for the aspiration of the cortex and for the insertion of intraocular lenses. The removal of the lens nucleus and the cortical material should be done by hand, rather than by phacoemulsification, which is a procedure carried out by a machine that has ultrasonic power and suction. MSICS has been linked to excessive handling and damage to the iris, posterior capsular rent and zonulodialysis [7].

The study in the United States reported that the prevalence of IAP was 9.1%, hypotony 4.5%, hyphema 4.5%, and compaction of the cornea was 4.5% after manual small incision cataract surgery [8].

Other authors have assessed the safety of MSICS however few studies have been done outside Pakistan [8,9] and none so far has been done to assess the early post-operative problems in Pakistan. Cost-effectiveness and high volume practice makes MSICS a widely used approach in Pakistan, and it is the leading cause of preventable blindness. Although there is a strong argument for its use, MSICS has been linked with early post-operative

complications which could impact surgical outcomes, but most of the available evidence is from overseas studies with limited local data available. The overall objective of this study is to find the incidence and nature of early complications after MSICS in our population, so as to provide evidence for optimizing surgical outcomes, patient counseling and healthcare planning.

### **Methodology:**

This cross-sectional study was design to determine the occurrence of post-operative complications after MSICS and was carried out in the Department of Ophthalmology at Hayatabad Medical Complex, Peshawar from September 2020 to 2021. The sample size was determined to be 135 patients, based on the WHO sample size calculator, at 95% confidence interval, 3.5% margin of error, and an expected prevalence of 4.5% for corneal decompensation after MSICS [8]. Consecutive sampling technique was used to include the patients in the study. The inclusion criteria was patients of either gender, age 35 to 70 years, undergoing cataract surgery, and cataract duration > 6 months. Excluded patients were those with any zonular weakness, posterior polar cataract, corneal dystrophy/pathology, status, post-uveitis cataract, pseudo exfoliation, and traumatic cataract.

Cataract diagnosis was made when there was clinically significant lens opacity detected by slit-lamp biomicroscopy that resulted in visual impairment and warranted surgical intervention. The severity of cataract was determined preoperatively using the Lens Opacities Classification System III (LOCS III).

Post-operative complications included: IOP (>21 mm Hg on tonometry), hypotony (<12 mm Hg on tonometry), hyphema (pooling or collection of blood in the anterior chamber), corneal decompensation (cornea guttata, stromal density, or Descemet's membrane folds by slit lamp).

Study obtained approval from IRB with Ref No. 224/HEC/B&PSC/19 on 18th

December, 2019. After giving informed consent, demographic data and clinical details (age, sex, duration of complaint) were gathered. Peribulbar anesthesia was used for the MSICS. A fornix-based conjunctival flap was created and hemostasis was achieved by bipolar diathermy cautery. A partial thickness curvilinear scleral incision was performed with a 6-8 mm slit, 3 mm posterior to the limbus with the creation of a side port at 9 o'clock. Viscoelastic material was used to deepen the anterior chamber and continuous curvilinear capsulorhexis was performed. Several hydro-dissections were carried out to facilitate the passage of the nucleus into the anterior chamber, and this was then removed from the chamber by hydrostatic pressure. A posterior chamber intraocular lens (IOL) was inserted in the bag and the residual cortex was evacuated using a Simcoe cannula. Viscoelastic was aspirated and side port closed with moistening of the stroma.

All surgery was carried out by a consultant ophthalmologist who has three years of post fellowship training in MSICS. Consistency in evaluation by same consultant on the first day after surgery to assess postoperative complications. A structured proforma was used to record any complications and IBM-SPSS version 27 was used to assess the complications. Age, duration of complaint, duration of procedure were recorded as mean  $\pm$  SD, gender, side of eye, post-operative problems were recorded as

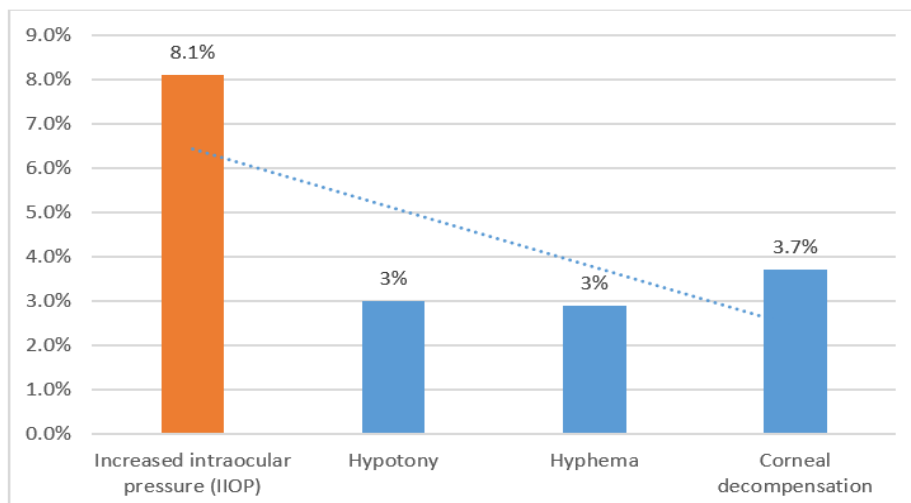
frequencies and percentages. The problems after the surgery were categorised according to age, gender, eye side, duration of complaint and procedure duration. Associations were evaluated with the Fisher Exact test, and the p-value of  $\leq 0.05$  was used as the criterion for significance.

### Results:

This study consists of 135 patients with a mean age of  $56.5 \pm 5.3$  years, mean duration of complaints of  $15.5 \pm 4.4$  months, and mean procedure duration of  $23.1 \pm 4.1$  minutes. Among participants, 72 (53.3%) were male, and 63 (46.7%) were female, with most surgeries performed on the left eye 96 (71.1%) compared to the right eye 39 (28.9%).

Based on preoperative grading using LOCS III, nuclear sclerosis grade III–IV was observed in 74 (54.8%) patients, followed by grade I–II in 27 (20%) patients, and grade V–VI in 20 (14.8%) patients. Cortical opacities were present in 27 (20%) patients, while posterior subcapsular opacities were noted in 14 (10.4%) patients, either in isolation or in combination with nuclear changes. Some patients demonstrated mixed morphological patterns.

The total post-operative complications was 24 (17.78%), included IOP 11 (8.1%), hypotony 4/24 (3%), hyphema 4 (3%), and corneal decompensation 5 (3.7) (Figure 1).



**Figure 1:** Frequency of Post-Operative Complications

In this study, postoperative complications were analyzed across baseline and procedural variables. No significant association was found between age, gender, side of eye, or duration of complaints and the occurrence of IOP, hypotony, hyphema, or corneal decompensation (all  $p > 0.05$ ). However, longer procedure duration ( $>20$  minutes) showed a

statistically significant association with increased IOP ( $p = 0.020$ ), while its relation to other complications was not significant. Patients with a complaint duration of more than 12 months tended to have a higher frequency of complications, but these associations did not reach statistical significance.

Table 1: Stratification of Postoperative Complications

Variable		Increased IOP n (%)	p-value	Hypotony n (%)	p-value	Hyphema n (%)	p-value	Corneal Decompensation n (%)	p-value
Age (years)	35–50	1(5.6%)	0.666	0(0%)	0.426	1(5.6%)	0.486	0(0%)	0.371
	51–70	10(8.5%)		4(3.4%)		3(2.6%)		5(4.3%)	
Gender	Male	6(8.3%)	0.933	1(1.4%)	0.249	2(2.8%)	0.892	2(2.8%)	0.543
	Female	5(7.9%)		3(4.8%)		2(3.2%)		3(4.8%)	
Side of Eye	Left	7 (7.3%)	0.568	4(4.2%)	0.196	3(3.1%)	0.862	5(5.2%)	0.146
	Right	4(10.3%)		0(0%)		1(2.6%)		0(0%)	
Complaints Duration (months)	6–12	0(0%)	0.064	0(0%)	0.278	0(0%)	0.278	0(0%)	0.223
	$>12$	11(10.5%)		4(3.8%)		4(3.8%)		5(4.8%)	
Procedure Duration (min)	$\leq 20$	0(0%)	0.02	0(0%)	0.172	0(0%)	0.172	0(0%)	0.126
	$>20$	11(11.8%)		4(4.3%)		4(3.8%)		5(5.4%)	

**Discussion:**

In our study first day post-operative complications were IOP 8.1%, hypotony 3%, hyphema 3% and corneal decompensation was 3.7%. Results of this study are comparable to a study conducted in United states which has shown that frequency of IOP was 9.1%, hypotony 4.5%, hyphema 4.5% and corneal decompensation was 4.5% after manual small incision cataract surgery [8]. MSICS is a safe and effective method for cataract removal, especially in developing countries, and has similar or better early results compared to Extra-capsular cataract extraction (ECCE) and

phacoemulsification[10-13,15]. Phacomorphic glaucoma may be difficult to perform as there is a higher chance of endothelial cell loss because the nucleus emulsifier is close to the endothelial cells during nucleus emulsification and patients have lower endothelial reserve<sup>16</sup>, and have a higher chance of shallow chamber, Iris prolapse, and peripheral capsulorrhexis tears. In such circumstances, a pars plana vitreous tap is recommended to extend the anterior segment, which helps to deepen the anterior chamber and allows for effective capsulectomy and cataract extraction [17]. A small-gauge, sutureless pars plana partial-core vitrectomy has also been

demonstrated to be an effective surgical technique to overcome these problems. The drawbacks are that the eye can't be directly visualized because of extensive cataract and there is a very small risk for retinal detachment, which was reported following small-gauge vitrectomy for various posterior segment conditions [15]. MSICS, on the other hand, does not require costly equipment such as phacoemulsification, and the anterior chamber is more stable due to the shelving scleral wound, resulting in less surgical problems.

Many things can cause hypotony following cataract surgery. Corneal edema, corneal Descemet's folds, shallow anterior chamber, retinal and optic disc oedema, retinal folds and choroidal detachment are common anatomic changes associated with chronic hypotony after cataract surgery, typically caused by a wound leak, hidden cyclodialysis or chronic inflammation [17]. In 2015, Alexander et al [18] reported hypotony as a possible complication that occurs on the first day of pars plana vitrectomy. Hypotony occurs in about 6% of patients shortly after surgery, indicating that improved wound formation might improve surgical outcomes [19]. Hypotony can be more or less depending upon the size and structure of the wound. Improper incisions were associated with decreased postoperative intraocular pressures [20]. Clear corneal cataract surgery may leave the eyes with low intraocular pressure, and the margins may gap, increasing the risk of introduction of organisms into the aqueous<sup>21</sup> which may result in endophthalmitis. One of the estimates is 1.6% cases needed suturing because of wound leaking. The leak can also occur in the scleral tunnel and limbal [22]. In 2014, Hayashi et al. [23] reported that scleral tunnel incisions have superior ability to self-seal and water tightness than transparent corneal incisions.

Our study highlights that early post-operative IOP elevation is more likely in procedures lasting longer than 20 minutes. The occurrence of hypotony, hyphema, and

corneal decompensation was low. Although 71.1% of surgeries in our study were performed on the left eye, this was due to consecutive patient enrollment during the study period and was not the result of intentional selection. No systematic preference for operating on the left eye was applied.

The study limitations include, early (first-day) complications assessment, so long-term outcomes such as posterior capsular opacification or final visual acuity were not evaluated. Small sample size and a single-center design may limit generalizability. The sample size for some complications was small, reducing statistical power. Postoperative assessments relied on clinical examination, which may introduce observer variability. Although procedure duration was analyzed as a risk factor for complications, the underlying reasons for longer surgeries, like dense cataract, small pupil, or intraoperative difficulties, were not recorded in this study. Future studies should document these factors to more accurately assess their impact on postoperative outcomes. Also future studies should include larger, multicenter cohorts and follow-up beyond the first postoperative day to assess long-term outcomes objectively.

### **Conclusion:**

Manual small incision cataract surgery is a safe procedure with a low frequency of early post-operative complications. In this study, first-day complications included IOP (8.1%), hypotony (3%), hyphema (3%), and corneal decompensation (3.7%). Surgeons should exercise care during surgery to minimize early complications, particularly in procedures of longer duration.

### **References:**

1. Lee MD, Chen SP, Chen TA, Leibold C, Li Z, Fisher AC, et al. Characteristics of cataract surgery patients influencing patient satisfaction scores. *J Cataract*

- Refract Surg. 2019 Apr;45(4):437-42.
2. Grzybowski A, Kanclerz P, Muzyka-Woźniak M. Methods for evaluating quality of life and vision in patients undergoing lens refractive surgery. *Graefes Arch Clin Exp Ophthalmol.* 2019 Jun;257(6):1091-9.
  3. Chew FLM, Qurut SE, Hassan I, Lim ST, Ramasamy S, Rahmat J. Paediatric cataract surgery in Hospital Kuala Lumpur - A 5-year review of visual outcomes. *Med J Malaysia.* 2019 Feb;74(1):15-9.
  4. Comba OB, Pehlivanoglu S, Bayraktar Z, Albayrak S, Karakaya M. Pantoe agglomerans endophthalmitis after phaco surgery: the first case in literature. *Ocul Immunol Inflamm.* 2020;28(3):479-82.
  5. Li E, Margo CE, Greenberg PB. A primary care provider's guide to cataract surgery in the very elderly. *Fed Pract.* 2019 Apr;36(4):176-80.
  6. Singh K, Misbah A, Saluja P, Singh AK. Review of manual small-incision cataract surgery. *Indian J Ophthalmol.* 2017 Dec;65(12):1281-8.
  7. Paolo L. Manual small-incision cataract surgery helps meet challenges in developing world [Internet]. *Ocular Surgery News U.S. Edition*; 2020 [cited 2020 May 15]. Available from: <https://www.healio.com/ophtalmology/cataract-surgery/news/print/ocular-surgery-news/%7B20d3e58d-1b11-4c35-9873-73bdae5f5fab%7D/manual-small-incision-cataract-surgery-helps-meet-challenges-in-developing-world?page=4>
  8. Zafar S, Chen X, Sikder S, Srikumaran D, Woreta FA. Outcomes of resident-performed small incision cataract surgery in a university-based practice in the USA. *Clin Ophthalmol.* 2019;13:529-34.
  9. Garima A, Hansa T, Kamini A. Visual outcome and major surgical complications of manual small incision cataract surgery versus extra capsular cataract extraction performed by resident doctors in a regional institute of ophthalmology. *Gujarat Medical J.* 2015;70(2):31-36.
  10. Gogate PM, Deshpande M, Wormald RP, Deshpande R, Kulkarni SR. Extracapsular cataract surgery compared with manual small incision cataract surgery in community eye care setting in western India: A randomised controlled trial. *Br J Ophthalmol.* 2003;87(6):667-72.
  11. Natchiar G, Dabralkar T. Manual small incision sutureless cataract surgery: An alternative technique to instrumental phacoemulsification. *Oper Tech Cataract Refract Surg.* 2000;3:161-70.
  12. Ruit S, Tabin G, Chang D, Bajracharya L, Kline DC, Richheimer W, et al. A prospective randomized clinical trial of phacoemulsification vs manual sutureless small-incision extracapsular cataract surgery in Nepal. *Am J Ophthalmol.* 2007;143(1):32-8.
  13. Wormald RP. Phacoemulsification vs small-incision manual cataract surgery: An expert trial. *Am J Ophthalmol.* 2007;143(1):143-5.
  14. Venkatesh R, Tan CS, Kumar TT, Ravindran RD. Safety and efficacy of manual small incision cataract surgery for phacolytic glaucoma. *Br J Ophthalmol.* 2007;91(3):279-81.
  15. Arevalo JF, Berrocal MH, Arias JD, Banaee T. Minimally invasive vitreoretinal surgery: is sutureless vitrectomy the future of vitreoretinal surgery? *J Ophthalmic Vis Res.* 2011 Apr;6(2):136-44.

16. Chang DF. Pars plana vitreous tap for phacoemulsification in the crowded eye. *J Cataract Refract Surg.* 2001;27(12):1911-4.
17. Daniel E, Pistilli M, Pujari SS, Kamaz RO, Nussenblatt RB, Rosenbaum JT, et al. Risk of hypotony in non-infectious uveitis. *Ophthalmology.* 2012;119(11):2377-85.
18. Alexander P, Michaels L, Newsom R. Is day-1 postoperative review necessary after pars plana vitrectomy? *Eye (Lond).* 2015;29(11):1489-94.
19. Shingleton BJ, Rosenberg RB, Teixeira R, O'Donoghue MW. Evaluation of intraocular pressure in the immediate postoperative period after phacoemulsification. *J Cataract Refract Surg.* 2007;33(11):1953-7.
20. Masket S, Belani S. Proper wound construction to prevent short-term ocular hypotony after clear corneal incision cataract surgery. *J Cataract Refract Surg.* 2007;33(3):383-6.
21. Al Mahmood AM, Al-Swailem SA, Behrens A. Clear corneal incision in cataract surgery. *Middle East Afr J Ophthalmol.* 2014;21(1):25-31.
22. Monica ML, Long DA. Nine-year safety with self-sealing corneal tunnel incision in clear cornea cataract surgery. *Ophthalmology.* 2005;112(6):985-6.
23. Hayashi K, Tsuru T, Yoshida M, Hirata A. Intraocular pressure and wound status in eyes immediately after scleral tunnel incision and clear corneal incision cataract surgery. *Am J Ophthalmol.* 2014;158(2):232-41.

#### **Authors Contribution**

Concept and Design: Shehroze Bin Masood  
Data Collection / Assembly: Shehla Khan, Muhammad Sajid Khan  
Drafting: Fahad Zafar Zafar, Sohaib Ali<sup>2</sup>, Ehsan Sayyed  
Statistical expertise: Masiha Shafee  
Critical Revision: Shehroze Bin Masood